



Chronic post sternotomy pain: the role of sternal wire removal—a review

Elsayed Elmistekawy¹, Ahmed Attia²

¹Cardiac Surgery Division, University of Ottawa Heart Institute, Ottawa, Canada; ²Cardiac Surgery Department, Saud Albabtain Cardiac Center, Dammam, Saudi Arabia

Contributions: (I) Conception and design: E Elmistekawy; (II) Administrative support: None; (III) Provision of study materials or patients: None; (IV) Collection and assembly of data: All authors; (V) Data analysis and interpretation: None; (VI) Manuscript writing: All authors; (VII) Final approval of manuscript: All authors.

Correspondence to: Elsayed Elmistekawy, MD. Cardiac Surgery Division, University of Ottawa Heart Institute, Ottawa, K1y4W7, Canada.

Email: elmistekawy@yahoo.com.

Abstract: Millions of patients worldwide undergo cardiac surgery via median sternotomy. Many of those patients suffer from chronic pain. Late pain after median sternotomy usually considered insignificant; however recently chronic postoperative pain has been considered as an annoying problem and gaining more attention in order to understand the nature and management of it. In this review we will shed some lights on the incidence, etiology and management of chronic postoperative pain after cardiac surgery with a focus on the role of sternal wires removal as a management option for chronic post sternotomy pain.

Keywords: Sternotomy; pain; sternal wires

Received: 16 February 2020; Accepted: 06 March 2020; Published: 25 September 2020.

doi: 10.21037/amj.2020.03.06

View this article at: <http://dx.doi.org/10.21037/amj.2020.03.06>

Definition

Generally, chronic pain post-surgery is the pain that occurs either continuously or intermittently in the location of surgery, lasts beyond the normal rehabilitation period of a tissue for about three months after surgery and different from that suffered pre-operatively (1,2); However, some authors identify 12 months as the minimum duration of pain to be considered chronic. Some authors define chronic pain with no fixed duration but any pain that extends beyond the expected period of healing (1).

To define chronic post sternotomy pain, the pain must develop post-operatively at the median sternotomy location; it must be of at least 2 months after surgery and other causes of pain (including the possibility that the pain is from a pre-existing condition) are excluded (3).

Importance and incidence of chronic post sternotomy pain

A significant number of patients who undergo median

sternotomy for heart surgery (estimated to be over 2 million annually); suffer from persistent pain defined as chronic post-sternotomy pain (4). In the immediate period after surgery; severe uncontrolled pain negatively affects patient recovery after cardiac surgery. Untreated pain may lead to adverse hemodynamic consequences such as tachycardia, arrhythmias and hypertension; can lead to pulmonary complications such as atelectasis, pneumonia and coagulation disorders such as hypercoagulability and platelet activation, it also can lead to sleep, mood and behavioral changes, all of these consequences of pain can result in increased intensive care unit or hospital length of stay, hospital readmission, prolonged recovery and negatively affect quality of life on those affected (5,6).

In literature, there is a wide variation of the incidence of chronic post-sternotomy pain, this variation can be attributed to variations in definitions, different patient characteristics and retrospective nature of these studies. Chronic pain after coronary artery bypass surgery, was estimated to occur in 25–50% of patients and the incidence

of severe pain is 5–10% of them (5,7-12).

Studies reported a 20.6% brachial damage during cardiac surgery that can result in chronic pain post sternotomy (1,8,13,14).

In a study conducted by Meyerson *et al.*, ninety patients (28%) of 318 patients had chronic post-sternotomy pain one year after operation. Forty-one (13%) patients reported moderate degree of pain and 14 patients (4%) reported the pain as severe (5).

In another study, Gjeilo *et al.* included both bypass surgery and valve surgery patients, 521 patients were questioned 6 and 12 months post operatively. Pain was measured using the Brief Pain questionnaire and health related Quality of Life, Persistent pain was reported by 11% of patients at 6 and 12 months after surgery. About half of these patients reported to have chronic pain at both assessments, while an equal number of patients reported pain at either 6 or 12 months (15). Prevalence of chronic pain decreased with age; older patients are less likely to report pain (55% in those aged under 60 years compared with 34% in patients over 70 years). Patients with pre-operative angina and those with body mass index >25 at the time of surgery were more likely to report chronic pain (1).

Causes and mechanisms of chronic post sternotomy pain

After ruling out myocardial ischemia or sternal wound infection as possible causes for chest pain; the etiology of post-sternotomy pain can be theoretically attributed to two main causes, first nerve injury and second musculoskeletal factors (1).

Nerve injury factors

Defalque and Bromley (16) attributed chronic post sternotomy pain to the development of scar-entrapped neuromas at the sternotomy site caused by sternal wires and intercostal neuralgia, due to damage of the intercostals nerves during internal mammary artery (IMA) harvesting. Brachial plexus injury from over retraction of sternal plates, the later could also cause upper extremity pain, chest pain in dermatome T1, and painful sternum (12,13,16-20).

Nerve injury originates mostly from direct surgical injury of the peripheral nerves, or as a consequence of active inflammation resulting in neuropathic pain which is characterized by loss of sensation, hypersensitivity of the affected body area with allodynia and spontaneous,

sometimes paroxysmal pain (21).

Damage to the anterior rami of the intercostal nerves can results from trauma during harvest of the IMA, sternal retraction, electrocautery, drainage tubes insertion and sternal wires application. IMA harvesting per se has been reported to predispose to post sternotomy pain in many studies (22-24); however, this predisposition to increased postoperative pain after IMA harvest has not been detected in the most recent larger studies (5,15), moreover; intraoperative nerve conduction study although confirmed intercostal nerves damage during thoracic surgery procedures but intercostal nerve injury was not indicative of long-term pain (24). Also valve surgery patients are likely report chronic post sternotomy pain as those undergoing IMA harvesting; suggesting trauma during internal artery dissection is not the only mechanism for this post sternotomy pain (5).

The methods of harvesting (pedicled versus skeletonized) is a matter of controversy in literature as regards to reducing post sternotomy pain. Skeletonizing IMA graft has been proposed as one way to reduce postoperative pain, in addition to other benefits of skeletonization such as improving graft blood flow and reducing the incidence of sternal infection. In a randomized, double-blind within patient comparison of skeletonized versus pedicled IMA, Boodhwani *et al.* found that postoperative pain was similar at discharge and at 4 weeks after surgery, but was significantly less in the skeletonized group compared with the pedicled group 3 months after surgery, In addition, sensory deficits to pinprick sensation were reduced at 4 weeks and 3 months (17% *vs.* 50%, $P=0.002$) after surgery in the skeletonized side of the sternum (25). In contrast to this study, skeletonizing IMA did not reduce chronic post-sternotomy pain in a retrospective questionnaire-based study of 380 patients at 31 months after surgery (26); post sternotomy pain was present in 100/221 (45%) of patients in the skeletonized and 63/125 (50%) in the pedicled IMA groups, with no significant difference between the two groups. This finding may suggest that ischemic injury, not direct mechanical injury to the intercostal nerves is the mechanism of underlying post sternotomy pain (26).

Musculoskeletal factors

Musculoskeletal factors that might be the cause of chronic post-sternotomy pain include sternal fracture, incomplete healing of the sternum and sternal instability, sternocostal chondritis, rib or costal fracture, broken and or migration

of the steel sternal wire towards the skin, and sternal pseudoarthrosis (27,28).

Other contributing factors

Two other factors that may play a role in development of post sternotomy pain, one is the rare occurrence of hypersensitivity reaction against the metal wire and the other factor is the psychological factor; central sensitization to pain with an exaggerated response to moderate peripheral pain stimuli. With time, the original peripheral stimuli may disappear, but the central sensation remains, leaving the central pain independent of peripheral stimuli. The result is an exaggerated response to minor pain stimuli (hyperalgesia), as well as pain in response to normally non-nociceptive stimuli (allodynia) (5,28,29).

Risk factors of chronic post sternotomy pain

In their study Laura van Gulik and colleague found that non-elective surgery, re-sternotomy shortly after the original surgery, severe pain on the third postoperative day, and female gender are independent predictors for the development of chronic thoracic pain (4). Allergy to the wire used for sternum closure, younger age, and the use of the IMA can be also considered risk factors (20,30). It has been suggested that the severity of acute postoperative pain and greater need for analgesics during the first few days after surgery may predict future chronic pain. That reflects the importance of management of the acute postoperative pain for the purpose of disrupting the possible peripheral and central neural processes responsible for the transition to a chronic pain (31).

Excessive sternal retraction can result in a trauma to muscles, bones, tendons and ligaments beside its effects on the brachial plexus. A local inflammatory component will usually follow the surgery, in addition to a general inflammatory response due to cardiopulmonary bypass (21).

Preoperative anxiety, depression and catastrophizing (tendency to exaggerate the threat value of pain and to feel helpless in the context of pain), are associated with higher rates of chronic post sternotomy pain (32).

Management of chronic post sternotomy pain

It is essential to rule out important causes of chronic anterior wall pain such as myocardial ischemia, and

mediastinitis in every cardiac surgery patient presenting with chest pain.

The management of chronic post sternotomy pain requires a multidisciplinary approach that starts first with preventive measures that involves intensive perioperative psychological, medical, physical therapy, and second utilizing pharmacological and non-pharmacological measures aimed at preventing and treating the factors that increase the risk of chronic post sternotomy pain and associated negative consequences (33).

The surgical therapy includes sternal wire removal; which may be an effective treatment for pain in a subgroup of patients. If the pain persists after wire removal, referral to a chronic pain management specialist is recommended.

Pharmacological treatment

Acute postoperative pain management

High doses of intravenous opioids are usually used for anesthesia during surgery, and parenteral opioids are used in the early post-operative period for pain relief (34). There is a large list of added pain control medications to Opioid postoperatively in order to potentiate the analgesic effects and decrease the dose and side effects of opioid such as paracetamol, Ketamine and NON-steroidal anti-inflammatory (35-37).

Chronic pain management

A wide range of analgesics have been used in the treatment of chronic pain, opioid, non-opioid analgesics (simple and topical), non-steroidal anti-inflammatory drugs (NSAIDs), other anti-neuropathic drugs.

Opioids

Opioids have been used increasingly in chronic pain management. Wide range of opioids are being used including weak opioids such as codeine and tramadol and strong opioids such as morphine, diamorphine, hydromorphone, oxycodone, fentanyl, buprenorphine and methadone, there is no strong evidence that one opioid is better than another, but for an individual patient, one opioid can have a better effect versus adverse effect profile than others (38).

NSAID

NSAID has a modest beneficial effect in patients with chronic pain. No difference has been observed between different NSAIDs or between non-selective and cyclooxygenase (COX)-2 selective NSAIDs.

Gastrointestinal, renal and cardiac and neurologic adverse effects are well established risks of long term regular NSAID treatment (39,40).

Anti-epilepsy drugs

Gabapentin has moderate beneficial effect in chronic pain relief; compared with diclofenac on chronic post sternotomy pain, gabapentin is superior than diclofenac. The relief of symptoms with gabapentin persists longer than diclofenac (41). Gabapentin is safe and effective in pain control with mild adverse effects commonly dizziness, somnolence, peripheral edema, and gait disturbance (42).

Pregabalin is another anticonvulsant with chemical similarity to gabapentin, Pregabalin has been proved to reduce excitatory neurotransmitter release and preventing hyperalgesia and central sensitization. Many studies proved its usefulness in controlling acute as well as chronic post sternotomy pain, in addition (43).

Carbamazepine is another anticonvulsant that may be considered for the treatment of neuropathic pain (39).

There is little evidence that other anti-epilepsy drugs such as sodium valproate, Lamotrigine and phenytoin are effective in treatment for patients with chronic pain (39,44).

Non-pharmacological approach for managing this pain

Technical measures

At the time of surgery, different measures can be utilized in order to minimize the pain that may originate from peripheral nerve damage or tension on brachial plexus. Examples of these measures are: meticulous median sternotomy that is performed correctly in the mid line, caudal placement of the retractor prevent over retraction and pressure on the brachial plexus, IMA harvesting using asymmetrical traction retractors also prevent traction to the brachial network and lastly robust sternal closure (13).

Psychological intervention

Psychotherapy has an established role in the effective multidisciplinary treatment of chronic pain; however, it has rarely been central in the management of postsurgical pain, despite consistent findings that psychological factors such as pain catastrophizing, depression, anxiety, and posttraumatic symptoms are predictive of chronic post sternotomy pain. In persistent post sternotomy pain, it is becoming crucial to involve psychological services in the management of this pain (45).

Preoperative patient education may play an important role in the prevention of post sternotomy pain as patients

undergoing cardiac surgery might not be aware of the risk of chronic pain and its potential detrimental effects on their well-being

Massage therapy

Massage therapy was found to be successful in relief chronic pain after median sternotomy. Massage therapy can be performed by patient's companion trained by a nurse or message therapist. This could beside alleviate the pain also promote the patient's family participation in the process of care (46).

Osteopathic manipulative treatment

Osteopathic manipulative treatment is another form of therapy that can be tried to reduce chronic pain after sternotomy, Osteopathic manipulative treatment is defined as: "The therapeutic application of manually guided forces by osteopathic physician, to improve physiologic function and/or support homeostasis that has been altered by somatic dysfunction". It was successful in alleviating post sternotomy pain without clear mechanisms. Osteopathic manipulative treatment may improve mechanical stress in the mediastinum and reduce the nociceptive afferent signals that develop following a surgical intervention, or could reduce the production of inflammatory cytokines (47).

Sternal wires removal

Closure of median sternotomy with stainless steel wires is the standard practice in cardiac surgery, wires closure technique is easy, fast, safe, reproducible and cheap. Stainless steel sutures are the most reliable and widely used material for closing the median sternotomy. Stainless steel sutures are non-absorbable suture that have an iron base and other elements such as chromium and nickel. The stainless-steel is characterized by tensile strength that help to keep sternal plates in position until healing is completed. It is resistant to corrosion and has minimal tissues reactivity (18,48).

Sensitivity to stainless steel sternal suture wires is very rare with few case reports on the literature, and allergy to the wires should be suspected in any patient who presents late with a chronic pain without identified causes or non-healing yet stable over granulating sternotomy wound (49).

The common practice to leave the wire in place as premature removal may precipitate sternal dehiscence or malunion resulting in chronic discomfort and functional disability.

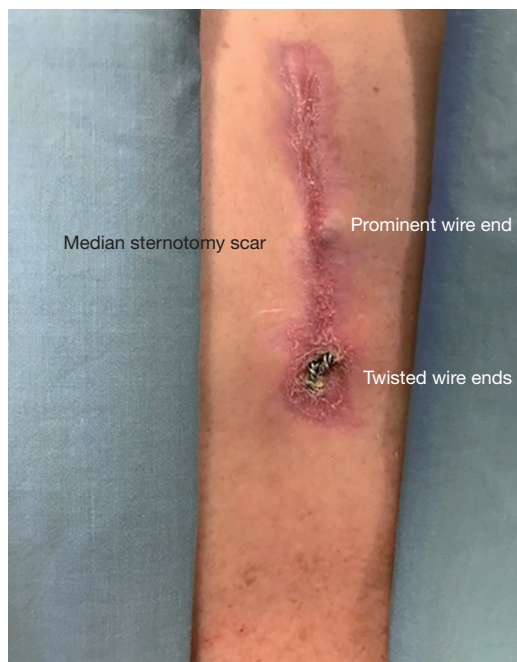


Figure 1 Sternal wires in skinny patients.

Indications of sternal wires removal

- (I) To gain reentry either for redo surgery or in acute postoperative situation;
- (II) Deep sternal wound infection and localized infection related to the sternal wires;
- (III) In skinny patients and those who lose weight, sternal wires can be palpable or even seen or rarely can erode through the skin, in those patients wire removal may be indicated to alleviate their discomfort (*Figure 1*);
- (IV) Sternal wire removal is indicated as a measure to treat post sternotomy chronic pain.

Sternal wires can provoke damage of the anterior rami of the intercostal nerves during insertion at the sternal margin of the intercostal spaces Defalque and Bromley suggest that results in a neuralgia associated with scar-entrapped neuromas (16).

Wire factors for development of chronic pain includes eversion of the twisted portion of the sternal wires, friction between the wires and tissues and wire fracture with the resultant broken parts or dehiscence can be also a source of post sternotomy pain. Rarely allergic reaction to the wire can be the source of chronic pain. Once other causes of anterior chest pain such as sternal instability, mediastinitis, and cardiac causes such as ischemia are excluded, sternal

wire removal is usually recommended.

In their study Zavaros *et al.* studied 165 patients who received sternal wire removal, the majority of the patients (92%) had relief from pain, while only 9 patients (8%) reported no change or worsening of the pain after wire removal (50).

In another study that included Ninety-five patients who received sternal wire removal for persistent anterior chest wall pain after median sternotomy, Nørgaard *et al.* found that wire removal results in a complete or partial relief of symptoms in 86% of patients, while 11% reported no change in symptoms, and 3% reported worsening of symptoms after wire removal. They also found that wire removal usually occurs more frequently in patients with allergies, patients receiving valve-related procedures, and patients that had been reoperated for surgical complications within the first month after the primary operation (51).

Rashidi *et al.* retrospectively studied 206 patients who underwent sternal wire removal for chronic pain in their institution, they reported complete relief of pain occurred in 83% of those patients, and 10% had some improvement of their symptoms and 7% no improvement of the pain (52).

Technique of sternal wire removal

Wire removal for chronic post sternotomy pain is usually a minimal risk procedure that can be done under local anesthesia supplemented with sedation or light general anesthesia and usually performed as a same day procedure. Wire removal can be performed through small intermittent incision over the wires to be removed or complete incision of the previous sternotomy scar. Wire removal should be done with extreme caution as a small but serious risk of injury of mediastinal structures adherent to the sternum specially the right ventricle by the sharp end of the wire in its way out. Wire removal is safely done by coiling around the wire holder tip as this method was found to be safer than direct pulling in experimental study (53).

Conclusions

Chronic post sternotomy pain is an important issue post cardiac surgery that can negatively affect the quality of life, patient satisfaction and productivity. Different explanations have been proposed but still we need to understand the nature of that pain. Different pharmacological and non-pharmacological measures are being used to alleviate post sternotomy pain, including sternal wires removal, the latter

is a minor procedure that can help the majority of those patients. Multidiscipline approach is required to manage those patients with post sternotomy pain.

Acknowledgments

The authors thank Amr Elfert and Nour Elmetekawy for their help in preparing and editing this manuscript.

Funding: None.

Footnote

Conflicts of Interest: Both authors have completed the ICMJE uniform disclosure form (available at <http://dx.doi.org/10.21037/amj.2020.03.06>). The authors have no conflicts of interest to declare.

Ethical Statement: The authors are accountable for all aspects of the work in ensuring that questions related to the accuracy or integrity of any part of the work are appropriately investigated and resolved.

Open Access Statement: This is an Open Access article distributed in accordance with the Creative Commons Attribution-NonCommercial-NoDerivs 4.0 International License (CC BY-NC-ND 4.0), which permits the non-commercial replication and distribution of the article with the strict proviso that no changes or edits are made and the original work is properly cited (including links to both the formal publication through the relevant DOI and the license). See: <https://creativecommons.org/licenses/by-nc-nd/4.0/>.

References

- Bruce J, Drury N, Poobalan S, et al. The prevalence of chronic chest and leg pain following cardiac surgery: a historical cohort study. *Pain* 2003;104:265-73.
- Joshi GP, Ogunnaike BO. Consequences of inadequate postoperative pain relief and chronic persistent postoperative pain. *Anesthesiol Clin North Am* 2005;23:21-36.
- Macrae WA. Chronic pain after sternotomy. *Acta Anaesthesiol Scand* 2001;45:927-8.
- van Gulik L, Janssen L, Ahlers J, et al. Risk factors for chronic thoracic pain after cardiac surgery via sternotomy. *Eur J Cardiothorac Surg* 2011;40:1309-13.
- Meyerson J, Thelin S, Gordh T, et al. The incidence of chronic post-sternotomy pain after cardiac surgery - a prospective study. *Acta Anaesthesiol Scand* 2001;45:940-4.
- Grosen K, Laue Petersen G, Pfeiffer-Jensen M, et al. Persistent post-surgical pain following anterior thoracotomy for lung cancer: a cross-sectional study of prevalence, characteristics and interference with functioning. *Eur J Cardiothorac Surg* 2013;43:95-103.
- Eti Aslan F. Pain in cardiac surgery and the nursing approach. *Turkish Journal of Thoracic and Cardiovascular Surgery* 2012;20:172-6.
- Kalso E, Mennander S, Tasmuth T, et al. Chronic post-sternotomy pain. *Acta Anaesthesiol Scand* 2001;45:935-9.
- Eisenberg E, Pultorak Y, Pud D, et al. Prevalence and characteristics of post coronary artery bypass graft surgery pain (PCP). *Pain* 2001;92:11-17
- Taillefer MC, Carrier M, Bélisle S, et al. Prevalence, characteristics, and predictors of chronic nonanginal postoperative pain after a cardiac operation: a cross-sectional study. *J Thorac Cardiovasc Surg* 2006;131:1274-80.
- Lahtinen P, Kokki H, Hynynen M. Pain after cardiac surgery: a prospective cohort study of 1-year incidence and intensity. *Anesthesiology* 2006;105:794-800.
- Vahl CF, Carl I, Müller-Vahl H, et al. Brachial plexus injury after cardiac surgery. The role of internal mammary artery preparation prospective study on 1000 consecutive patients. *J Thorac Cardiovasc Surg* 1991;102:724-9.
- Sharma AD, Parmley CL, Sreeram G, et al. Peripheral Nerve Injuries During Cardiac Surgery: Risk Factors, Diagnosis, Prognosis, and Prevention. *Anesth Analg* 2000;91:1358-69.
- Chong AY, Clarke CE, Dimitri WR, et al. Brachial plexus injury as an unusual complication of coronary artery bypass graft surgery. *Postgrad Med J* 2003;79:84-6.
- Gjeilo KH, Klepstad P, Wahba A, et al. Chronic pain after cardiac surgery: a prospective study. *Acta Anaesthesiol Scand* 2010;54:70-8.
- Defalque RJ, Bromley JJ. Poststernotomy neuralgia: A new pain syndrome. *Anesth Analg* 1989;69:81-2.
- Weber LD, Peters RW. Delayed chest wall complications of median sternotomy. *South Med J* 1986;79:723-7.
- Eastridge CE, Mahfood SS, Walker WA, et al. Delayed chest wall pain due to sternal wire sutures. *Ann Thorac Surg* 1991;51:56-9.
- Fine PG, Karwande SV. Sternal wire-induced persistent pain: a possible hypersensitivity reaction. *Ann Thorac Surg* 1990;49:135-6.
- Moore R, Follette M, Berkoff A. Poststernotomy fractures

- and pain management in open cardiac surgery. *Chest* 1994;106:1339-42.
21. Kehlet H, Jensen TS, Woolf CJ. Persistent postsurgical pain: risk factors and prevention. *Lancet* 2006;367:1618-25.
 22. Mailis A, Umana M, Feindel CM. Anterior intercostal nerve damage after coronary artery bypass graft surgery with use of internal thoracic artery graft. *Ann Thorac Surg* 2000;69:1455-8.
 23. Rowe MA, King KB. Long-term chest wall discomfort in women after coronary artery bypass grafting. *Heart Lung* 1998;27:184-8.
 24. Maguire MF, Latter JA, Mahajan R, et al. A study exploring the role of intercostal nerve damage in chronic pain after thoracic surgery. *Eur J Cardiothorac Surg* 2006;29:873-9.
 25. Boodhwani M, Lam BK, Nathan HJ, et al. Skeletonized internal thoracic artery harvest reduces pain and dysesthesia and improves sternal perfusion after coronary artery bypass surgery: a randomized, double-blind, within-patient comparison. *Circulation* 2006;114:766-73.
 26. Bar-El Y, Gilboa B, Unger N, et al. Skeletonized versus pedicled internal mammary artery: impact of surgical technique on post CABG surgery pain. *Eur J Cardiothorac Surg* 2005;27:1065-9.
 27. Woodring JH, Royer JM, Todd EP. Upper rib fractures following median sternotomy. *Ann Thorac Surg* 1985;39:355-7.
 28. van Leersum NJ, van Leersum RL, Verwey HF, et al. Pain symptoms accompanying chronic post sternotomy pain: a pilot study. *Pain Med* 2010;11:1628-34.
 29. Alston RP, Pechon P. Dysaesthesia associated with sternotomy for heart surgery. *Br J Anaesth* 2005;95:153-8.
 30. Cohen AJ, Moore P, Jones C, et al. Effect of internal mammary harvest on postoperative pain and pulmonary function. *Ann Thorac Surg* 1993;56:1107-9.
 31. Katz J, Jackson M, Kavanagh BP, et al. Acute pain after thoracic surgery predicts long-term post-thoracotomy pain. *Clin J Pain* 1996;12:50-5.
 32. Theunissen M, Peters L, Bruce J, et al. Preoperative anxiety and catastrophizing: a systematic review and meta-analysis of the association with chronic postsurgical pain. *Clin J Pain* 2012;28:819-41.
 33. Katz J, Weinrib A, Fashler R, et al. The Toronto General hospital Transitional Pain Service: development and implementation of a multidisciplinary program to prevent chronic postsurgical pain. *J Pain Res* 2015;8:695-702.
 34. Schwann NM, Chaney MA. No pain, much gain? *J Thorac Cardiovasc Surg* 2003;126:1261-4.
 35. McDaid C, Maund E, Rice S, et al. Paracetamol and selective and non-selective non-steroidal anti-inflammatory drugs (NSAIDs) for the reduction of morphine-related side effects after major surgery: a systematic review. *Health Technol Assess* 2010;14:1-153, iii-iv.
 36. Cattabriga I, Pacini D, Lamazza G, et al. Intravenous paracetamol as adjunctive treatment for postoperative pain after cardiac surgery: a double blind randomized controlled trial. *Eur J Cardiothorac Surg* 2007;32:527-31.
 37. Laskowski K, Stirling A, McKay P, et al. A systematic review of intravenous ketamine for postoperative analgesia. *Can J Anaesth* 2011;58:911-23.
 38. Chou R, Huffman H. Medications for acute and chronic low back pain: A review of the evidence for an American Pain Society American College of Physicians clinical practice guideline. *Ann Intern Med* 2007;147:505-14.
 39. Dworkin RH, Turk DC, Peirce-Sandner S, et al. Research design considerations for confirmatory chronic pain clinical trials: IMMPACT recommendations. *Pain* 2010;149:177-93.
 40. Derry S, Moore RA, Rabbie R. Topical NSAIDs for chronic musculoskeletal pain in adults. *Cochrane Database Syst Rev* 2012;(9):CD007400.
 41. Biyik I, Gülcüler M, Karabiga M, et al. Efficacy of gabapentin versus diclofenac in the treatment of chest pain and paresthesia in patients with sternotomy. *Anadolu Kardiyol Derg* 2009;9:390-6
 42. Moore RA, Wiffen PJ, Derry S, et al. Gabapentin for chronic neuropathic pain and fibromyalgia in adults. *Cochrane Database Syst Rev* 2011;(3):CD007938.
 43. Bialer M. Why are antiepileptic drugs used for nonepileptic conditions? *Epilepsia* 2012;53 Suppl 7:26-33.
 44. Gill D, Derry S, Wiffen PJ, et al. Valproic acid and sodium valproate for neuropathic pain and fibromyalgia in adults. *Cochrane Database Syst Rev* 2011;(10):CD009183.
 45. Wicksell RK, Olsson GL. Predicting and preventing chronic postsurgical pain and disability. *Anesthesiology* 2010;113:1260-1.
 46. Najafi SS, Rast F, Momennasab M, et al. The effect of massage therapy by patients' companions on severity of pain in the patients undergoing post coronary artery bypass graft surgery: a single-blind randomized clinical trial. *Int J Community Based Nurs Midwifery* 2014;2:128-35.
 47. Bordoni B, Marelli F, Morabito B, et al. Post-sternotomy pain syndrome following cardiac surgery: case report. *J Pain Res* 2017;10:1163-9.
 48. Malhotra A, Garg P, Bishnoi K, et al. Is steel wire closure

- of sternotomy better than polyester suture closure? *Asian Cardiovasc Thorac Ann* 2014;22:409-15.
49. Lopez J, Sachithanandan A, Leow M. Allergic reaction to stainless steel sternotomy wires requiring removal: A case report and literature review. *Med J Malaysia* 2016;71:142-3.
50. Zavaros I, Horke A, Doll N, et al. Persistent chest wall pain due to sternal wire sutures after median sternotomy. How effective is sternal wire removal? *Thorac Cardiovasc Surg* 2010. DOI: 10.1055/s-0029-1246675.
51. Nørgaard MA, Andersen TC, Lavrsen MJ, et al. The outcome of sternal wire removal on persistent anterior chest wall pain after median sternotomy. *Eur J Cardiothorac Surg* 2006;29:920-4.
52. Rashidi S, Elenbaas W, Hamad A, et al. Does removal of steel wires relieve post-sternotomy pain after cardiac surgery? *Asian Cardiovasc Thorac Ann* 2013;21:409-13.
53. Kachel E, Bank J, Shinfeld A, et al. The safest method of sternal wire extraction post-midsternotomy closure. *J Card Surg* 2009;24:59-61.

doi: 10.21037/amj.2020.03.06

Cite this article as: Elmistekawy E, Attia A. Chronic post sternotomy pain: the role of sternal wire removal—a review. *AME Med J* 2020;5:31.